

Fluorescence diagnostics of oral cancer

Laima Bloznelytė-Plėšnienė^{1,2},

Aleksandras Mordas¹,

Vytautas Čepulis¹,

Jonas Venius¹,

Jurgita Liutkevičiūtė-Navickienė¹,

Laimutė Rutkovskienė¹,

Valerijus Ostapenko¹,

Konstantinas Povilas Valuckas¹

¹*Institute of Oncology,
Vilnius University,
Vilnius, Lithuania*

²*Klaipėda University,
Klaipėda, Lithuania*

Background. Early detection of oral cancer improves the results of treatment. Fluorescence diagnostics (FD) helps to identify the real margins of malignant tumour. However, in some cases the artefactual fluorescence of healthy mucosa appears. The aim of this study was to investigate the possibilities of fluorescence diagnostics of oral cancer as a more sensitive, effective and more specific method of FD.

Materials and methods. A total of 84 patients with morphologically verified malignant tumours underwent fluorescence diagnostics. They were grouped into three groups. The first group consisted of 20 patients with malignant recurrent oral cancer, who underwent systemic (intravenous) photosensitizer administration (2.5 mg/kg). After 24–48 h, visual fluorescence diagnostics and spectroscopic measurements were performed. The second group consisted of 60 patients with different malignant tumours except oral cancer. They also underwent systemic (intravenous) photosensitizer administration (2.5 mg/kg). After 24–48 h, visual fluorescence diagnostics and spectroscopic measurements were performed. The third group consisted of 7 patients with malignant recurrent morphologically verified oral cancer; they underwent I/a FD. A catheter was inserted selectively into the feeding artery of the tumour via the superficial temporal artery. Photofrin (10 mg) was injected via the catheter directly into the tumour. Immediately after injection, 1 h and 4 h after injection, the visualization of mucosal tissues of the hypopharyngeal and oropharyngeal regions was performed under illumination of $\lambda = 405 \pm 5$ nm light. Spectroscopic investigations of malignant and healthy tissues were also performed. Besides, there was the fourth group which consisted of 30 healthy volunteers. They were provided no treatment. The visual fluorescence diagnostics and spectroscopic measurements of healthy mucosa were performed for these volunteers.

Results. A specific pink fluorescence of malignant tissue was noted while illuminating a tumour with violet light. The margins of fluorescence usually coincided with those of a malignant tumour. In doubtful cases, biopsy and morphological examination of the tissue were performed. All malignant tumours, except melanoma, showed a specific pink fluorescence when illuminated with violet light, and no fluorescence was noted in normal mucosa. However, in some cases glow artefacts were observed. We identified these “glow artefacts” – a non-specific lilac fluorescence – in the healthy mucosa of 20 patients (in 6 patients from the first group and in 14 from the second group). Usually, artefactual fluorescence was noted in the gums (in 18 patients from 20) and at the basis of the tongue (in 11 patients from 20). There was no artefactual fluorescence in 7 patients who underwent I/a FD.

Conclusions. Fluorescence diagnostics is useful for early detection of primary and recurrent malignant oral tumours, except melanoma. However, an artefactual fluorescence in the gums or in the basis of the tongue can appear. I/a FD allows avoiding this artefactual fluorescence.

Key words: fluorescence diagnostics, oral cancer, intra-arterial

INTRODUCTION

Early detection of oral cancer improves the results of treatment. One of the promising diagnostic methods is an optical method also known as optical biopsy. This diagnostics of malignant tumours is based on a quite selective accumulation of porphyrins in tumour tissue (1). Porphyrin-enriched tumour tissue irradiation with light of an appropriate wavelength leads to the emission of pink-red fluorescence. This principle is used as a diagnostic procedure and is called fluorescence diagnostics (FD). Light-induced FD is a noninvasive technique for the real-time characterization of superficial tissue layers (2). The method relies on differences in the fluorescence emission from various types of tissue.

In several studies, the different intensity of fluorescence in normal and tumour tissues has been exploited for photodiagnosics (3). The fluorescence from a normal tissue, excited near 400 nm, is higher than that from tumour in the range 450–550 nm, but lower in the range 600–700 nm (4), and by taking the ratio of red intensity (600–700 nm) over the blue / green intensity (450–550 nm) the contrast between tumour and the adjacent normal tissue is enhanced significantly (5).

Autofluorescence is emitted by different endogenous chromophores of the tissue. The total autofluorescence emission has a broad wavelength distribution as it represents the contribution from different chromophores (6). An intensive fluorescence in the red part of the spectrum has been observed for some types of malignant and premalignant lesions (7).

In order to enhance tumour demarcation, exogenous sensitizers can be administered (8, 9). The most popular sensitizer is the haematoporphyrin derivative Photofrin. In cases of both endogenously and exogenously administered porphyrins, the red tumour fluorescence appears under excitation near 400 nm. It has been used successfully in studies of malignant lesions in various organs (10–18). Both the autofluorescence of endogenous tissue and the fluorescence of a tumour-marking sensitizer have been investigated in these studies.

There are valuable articles on the fluorescence of lesions in the head and neck region (19–22). The results presented in these articles are promising and suggest further, more detailed studies.

Malignant tumours in the oral cavity and oropharynx are in many cases visualized by the naked eye, but early recurrent malignancies and precancerous lesions may be difficult to visualize, particularly when they appear in cicatrices (23). In these cases fluorescence diagnostics is valuable. It helps to identify the real margins of the malignant tumour. However, in some cases an artefactual fluorescence of healthy mucosa appears. It can be caused by oral mu-

cosa microorganisms. On the other hand, porphyrins from food can influence the artefactual fluorescence, too. It is important to avoid this artefactual fluorescence. We believe that intra-arterial fluorescence diagnostics (I/a FD) may be useful for that purpose (24, 25). Intra-arterial infusion of chemotherapy agents for oral cancer has been applied for several decades (26–30).

We were the first to start intra-arterial hematoporphyrin derivative mediated photodynamic therapy (i/a PDT) in the head and neck in 1990 (31, 32). This method allowed us to use small doses of the expensive sensitizer; moreover, there was no necessity for patients to avoid ultraviolet or sun radiation.

The aim of the present study was to investigate the possibilities of intra-arterial fluorescence diagnostics of oral cancer as a more sensitive, effective and more specific method of FD.

MATERIALS AND METHODS

A total of 84 patients with morphologically verified malignant tumours underwent FD. They were grouped into three groups.

The first group consisted of 20 patients with malignant recurrent oral cancer, who underwent systemic (intravenous) photosensitizer administration, followed by visual FD and spectroscopic measurements of malignant and healthy tissues.

The second group consisted of 60 patients with different malignant tumours except oral cancer. For these patients, the FD measurements and spectroscopic investigations of malignant and healthy tissues were performed, followed by sensitized tumour therapy.

The third group consisted of 7 patients that underwent I/a FD. They had malignant recurrent morphologically verified oral cancer. Also, there was the fourth group which consisted of 30 healthy volunteers. They were provided no treatment. The fluorescence visual diagnostics and spectroscopic measurements of healthy mucosa were performed for these volunteers.

There are three historically recognized methods of intra-arterial infusion (33) for oral cancer: conventional intra-arterial infusion via the superficial temporal artery (34, 35), superselective intra-arterial infusion via the femoral artery (Seldinger's method) (36, 37), and a new superselective intra-arterial infusion via the superficial temporal artery (38).

We used the most popular conventional intra-arterial infusion via the superficial temporal artery. A catheter was inserted selectively into the feeding artery of the tumour via the superficial temporal artery (Fig. 1). The depth of catheter installation was defined by the injection of methylene blue through the catheter (Fig. 2). When the tumour

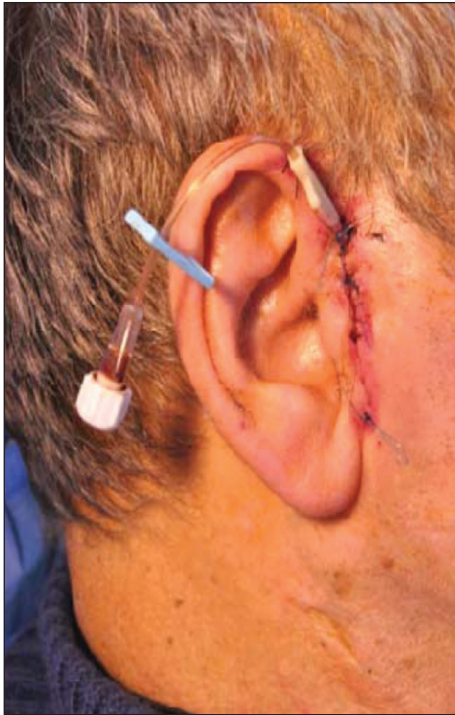

Fig. 1. Catheter inserted into the feeding artery of the tumour via the superficial temporal artery

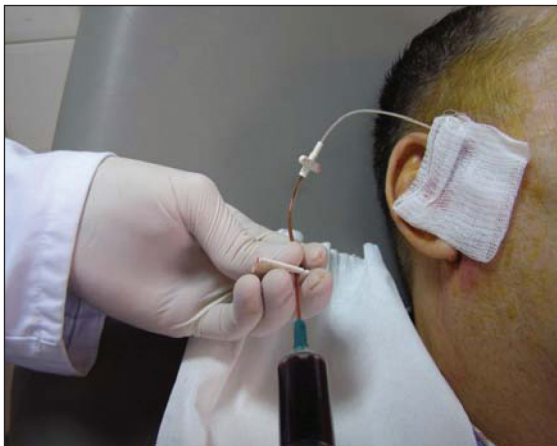


Fig. 2. Injection of methylene blue through a catheter

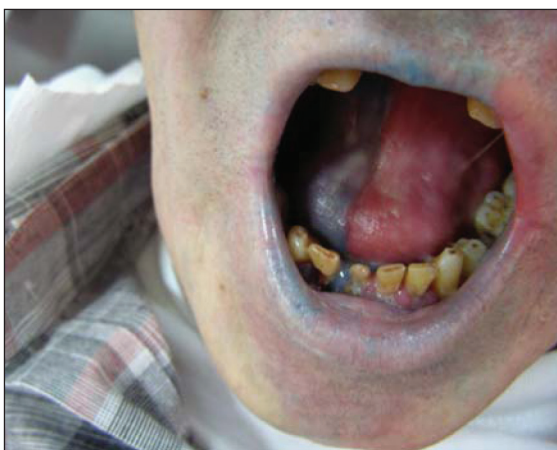

Fig. 3. Tumour tissues coloured in blue due to injection of methylene blue

tissues were coloured in blue, the catheter was fixed to the skin of the preauricular region (Fig. 3). Photofrin (10 mg) was injected via catheter directly into the tumour. Immediately after injection, 1 h and 4 h after injection, the visualization of mucosal tissues of the hypopharyngeal and oropharyngeal regions was performed under illumination of $\lambda = 405 \pm 5$ nm light.

Spectroscopic investigations of malignant and healthy tissues were also performed. The autofluorescence spectra were measured with a QE65000 fiber spectrometer (Ocean Optics). A special bifurcated fiber bundle probe (Ocean Optics) was used to register the fluorescence signal from particular places in the patient's mouth. It was composed of a bundle of quartz fibers: the central one (200 μm in diameter) for excitation and six (200 μm in diameter) situated around the excitation fiber – for fluorescence detection. The fluorescence was excited with 405 ± 5 nm wavelength light. Four different places of healthy oral mucosa – soft palate, the flank of the tongue, the mucosa of the cheek and gum, and one place of healthy chest skin were investigated in all patients. Biopsy and morphological examination of tissues from luminous and surrounding nonluminous sites were carried out after spectroscopic investigations.

The photosensitizer was injected i. v. (2.5 mg/kg), and after 24–48 h the visualization of mucosal tissues of the oropharyngeal region was performed under $\lambda = 405 \pm 5$ nm light. Four different places of healthy oral mucosa (soft palate, the flank of the tongue, cheek and gum mucosa) and one place of the healthy chest skin were investigated spectroscopically. Biopsy and morphological examination of luminous and surrounding nonluminous site tissues followed after spectroscopic investigations.

RESULTS AND DISCUSSION

A specific pink fluorescence of malignant tissue was noted while illuminating tumours with violet light 1–4 hours after i/a or 18–72 hours after i/v injection of the photosensitizer (Fig. 4). The margins of fluorescence usually coincided with the ones of malignant tumour. In doubtful cases, the biopsy and morphological examination of the tissue were performed. All malignant tumours, except melanoma, showed a specific pink fluorescence when illuminated with violet light, and no fluorescence was noted in normal mucosa (Fig. 5).

However, in some cases glow artefacts were observed (Fig. 6). We identified these “glow artefacts” as a non-specific lilac fluorescence in a healthy mucosa of 20 patients (6 patients from the first group and 14 from the second group). Usually, the artefactual fluorescence was noted in the gums (in 18 patients from 20) and at the basis of the tongue (in 11 patients from 20). In all cases of i/v

photosensitizer administration, the red fluorescence usually appeared 18–24 hours after intravenous injection of the photosensitizer. This fluorescence was evident for 3–6 days. In all cases of i/a photosensitizer administration, red fluorescence usually appeared one hour following the intraarte-

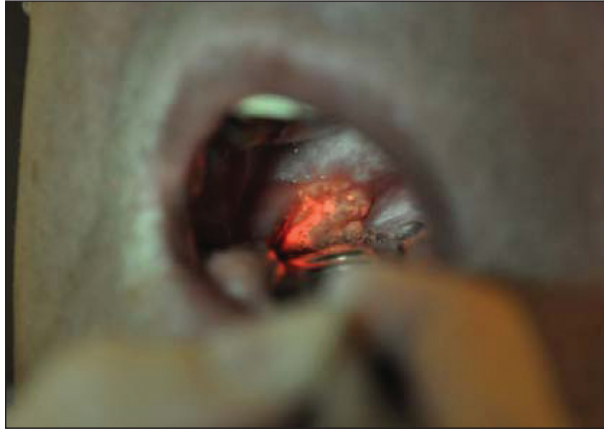


Fig. 4. Pink fluorescence of malignant tissue while illuminating tumour with violet light

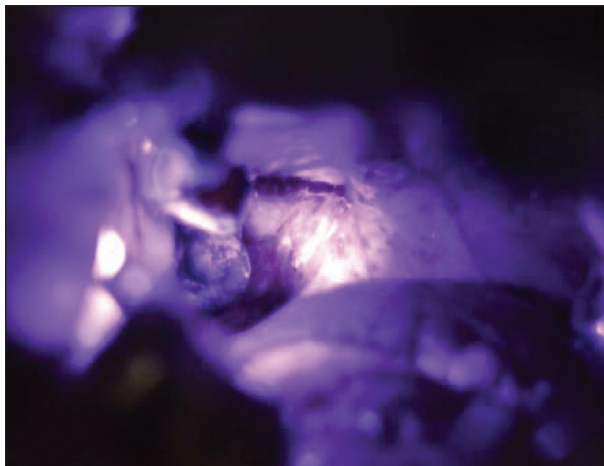


Fig. 5. No fluorescence was noted in normal mucosa when illuminated with violet light

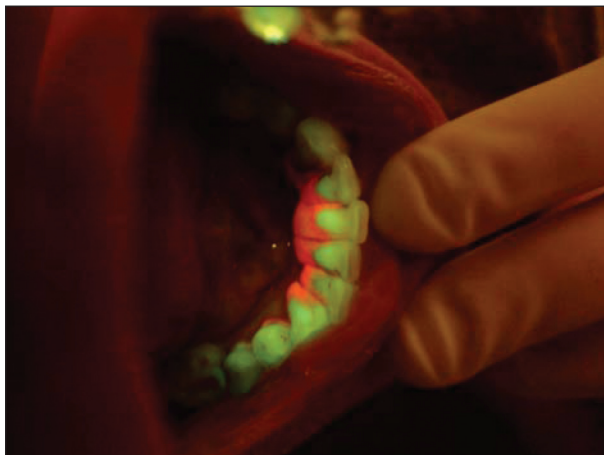

Fig. 6. Glow artefacts – a non-specific lilac fluorescence in healthy mucosa

rial injection of the photosensitizer. This fluorescence was evident for 2–3 days. There was no evidence of artefactual fluorescence in 7 patients who underwent i/a photosensitizer administration.

No generalized photosensitivity has been reported following intra-arterial photosensitizer administration. The reason is small doses (10 mg) of the photosensitizer while applying i/a FD. In intravenous FD, usually the dose of 2.5 mg/kg, i. e. 150–200 mg, was used.

The primary results of spectroscopic investigation indicate that after intra-arterial Photofrin administration the fluorescence of the photosensitizer in the chest skin was barely traceable (Fig. 7). This means that there was almost

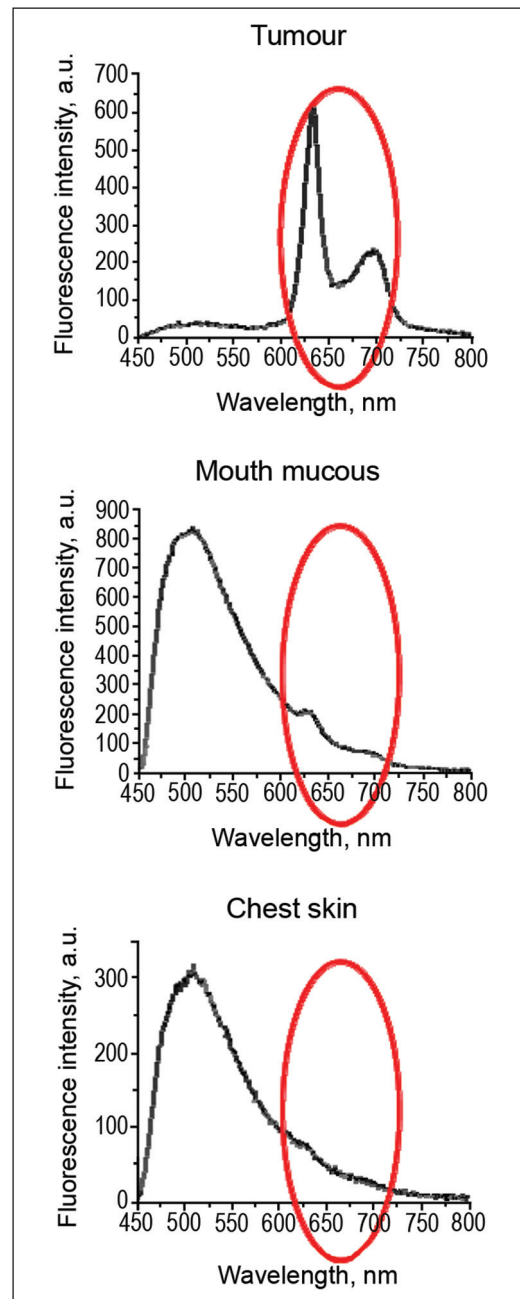


Fig. 7. Fluorescence intensity of Photofrin in different locations

no systematic accumulation of Photofrin. A low fluorescence intensity of the photosensitizer was registered in the surrounding healthy tissues near the tumour, and a very intensive fluorescence of Photofrin was registered in the tumour itself (Fig. 7).

CONCLUSIONS

Fluorescence diagnostics is useful for the early detection of primary and recurrent malignant oral tumours, except melanoma. However, artefactual fluorescence in the gums or at the basis of the tongue can appear. The i/a photosensitizer administration allows avoiding this artefactual fluorescence. It also enables to use small doses of the expensive sensitizer, and there is no necessity for the patient to avoid ultraviolet or sun radiation applying I/a FD.

ACKNOWLEDGEMENT

This work was supported in part by the Research Council of Lithuania under grant No. LIG-25/2010.

Received 10 June 2011

Accepted 13 June 2011

References

- Rydell R, Eker C, Andersson-Engels S, Krogdahl A, Wahlberg P, Svanberg K. Fluorescence investigations to classify malignant laryngeal lesions *in vivo*. *Head Neck*. 2008;30: 419–26.
- Chatterton K, Ray E, O'Brien TS. Fluorescence diagnosis of bladder cancer. *Br J Nurs*. 2006; 15: 595–7.
- Pham W. Detection and treatment of diseases using light. *IFMBE Proc*. 2010; 27: 19–22.
- Scott MA, Hopper C, Sahota A, Springett R, McIlroy BW, Bown SG et al. Fluorescence photodiagnosics and photobleaching studies of cancer lesions using ratio imaging and spectroscopic techniques. *Lasers Med Sci*. 2000; 15: 63–72.
- Andersson-Engels S, af Klinteberg C, Svanberg K, Svanberg S. *In vivo* fluorescence imaging for tissue diagnostics. *Phys Med Biol*. 1997; 42: 815–24.
- Zargi M, Fajdiga I, Smid L. Autofluorescence imaging in the diagnosis of laryngeal cancer. *Eur Arch Otorhinolaryngol*. 2000; 257: 17–23.
- Wang I, Clemente LP, Pratas RMG, Cardoso E, Clemente MP, Montan S et al. Fluorescence diagnostics and kinetic studies in the head and neck region utilizing low-dose δ -aminolevulinic acid sensitization. *Cancer Lett*. 1999; 135: 11–9.
- Ackroyd R, Kelty C, Brown N, Reed M. The history of photodetection and photodynamic therapy. *Photochem Photobiol*. 2001; 74(5): 656–69.
- Manjunath BK, Kurein J, Rao L, Murali Krishna C, Chidananda MS. Autofluorescence of oral tissue for optical pathology in oral malignancy. *J Photochem Photobiol B*. 2004; 73: 49–58.
- Kostron H, Plangger C, Fritsch E, Maier H. Photodynamic treatment of malignant brain tumors. *Wien Klin Wochenschr*. 1990; 102(18): 531–5.
- Burger M, Zaak D, Stief CG, Filbeck T, Wieland WF, Roessler W et al. Photodynamic diagnostics and non-invasive bladder cancer: is it cost-effective in long-term application? A Germany-based cost analysis. *Eur Urol*. 2007; 52: 142–7.
- Okunaka T, Kato H, Konaka C, Furukawa K, Harada M, Yamamoto Y. Photodynamic therapy of lung cancer with bronchial artery infusion of Photofrin. *Diagn Ther Endosc*. 1996; 2: 203–6.
- Nishiwaki Y, Nakamura S, Sakaguchi S. New method of photosensitizer accumulation for photodynamic therapy in an experimental liver tumor. *Lasers Surg Med*. 1989; 9(3): 254–63.
- Hillemanns P, Reiff J, Stepp H, Soergel P. Lymph node metastasis detection of ovarian cancer by porphyrin fluorescence photodetection: case report. *Lasers Med Sci*. 2007; 22: 131–5.
- Bloznelytė-Plėšnienė L, Rutkovskienė L. Photodynamic therapy of malignant and benign tumours in Lithuania. *Acta medica Lituanica*. 2007; 14(3): 193–200.
- Liutkevičiūtė-Navickienė J, Mordas A, Rutkovskienė L, Bloznelyte-Plesniene L. Skin and mucosal fluorescence diagnosis with different light sources. *Eur J Dermatol*. 2009; 19(2): 135–40.
- Liutkevičiūtė Navickienė J. Photodynamic (fluorescence) diagnostics of skin lesions [summary of doctoral dissertation]. Vilnius: Vilnius University; 2010.
- Liutkevičiūtė Navickienė J, Mordas A, Šimkutė S, Bloznelytė-Plėšnienė L. Odos navikų fluorescencinė diagnostika naudojant 5-aminolevulininę rūgšį ir jos metilintą esterį. *Medicina*. 2009; 45(12): 937–42.
- Rigual NR, Thankappan K, Cooper M, Sullivan MA, Dougherty T, Popat SR et al. Photodynamic therapy for head and neck dysplasia and cancer. *Arch Otolaryngol Head Neck Surg*. 2009; 135(8): 784–8.
- Schweitzer VG, Somers ML. Photofrin-mediated photodynamic therapy for treatment of early stage (T1-T2N0N0)SqCCa of oral cavity and oropharynx. *Lasers Surg Med*. 2010; 42: 1–8.
- Canavesi C, Fournier F, Cassarly WJ, Foster TH, Rolland JP. Illumination devices for photodynamic therapy

- of the oral cavity. *Biomed Opt Express*. 2010; 1(5): 1480–90.
22. Karakullukcu B, Oudenaarde K, Copper MP, Klop WMC, Veen R, Wildeman M et al. Photodynamic therapy of early stage oral cavity and oropharynx neoplasms: an outcome analysis of 170 patients. *Eur Arch Otorhinolaryngol*. 2011; 268: 281–8.
 23. Westbury G, Newton KA, Humble JG, Ford HT, Pegg DE, White WF. Recurrent cancer of head and neck. *Br Med J*. 1962; 1(5287): 1238–42.
 24. Moore RB, Xiao Z, Owen RJ, Ashforth R, Dickey D, Helps C et al. Photodynamic therapy of the canine prostate: intra-arterial drug delivery. *Cardiovasc Intervent Radiol*. 2008; 31: 164–76.
 25. Meissner O, Ostermeier M, Hoheisel M, inventors. Combined OCT catheter device and method for combined optical coherence tomography (OCT) diagnosis and photodynamic therapy (PDT). United States patent US 20090240154. 2009 Sep 24.
 26. Robbins KT, Howell SB, Williams JS. Intra-arterial chemotherapy for head and neck cancer: is there a verdict? *Cancer*. 2010; 116(9): 2068–70.
 27. Robbins KT. Is high-dose intensity intraarterial Cisplatin chemoradiotherapy for head and neck carcinoma feasible? *Cancer*. 2005; 103(3): 447–50.
 28. Rasch CRN, Hauptmann M, Schornagel J, Wijers O, Buter J, Gregor T et al. Intra-arterial versus intravenous chemoradiation for advanced head and neck cancer: Results of a randomized phase 3 trial. *Cancer*. 2010; 116(9): 2159–65.
 29. Sealy R, Helman P. Treatment of head and neck cancer with intra-arterial cytotoxic drugs and radiotherapy. *Cancer*. 1972; 30: 187–9.
 30. Vijaykrishnan R, Shields CL, Ramasubramanian A, Emrich J, Rosenwasser R, Shields JA. Irradiation toxic effects during intra-arterial chemotherapy for retinoblastoma: should we be concerned? *Arch Ophthalmol*. 2010; 128(11): 1427–31.
 31. Bloznelyte-Plesniene L, Cepulis V, Ponomarev I. Intra-arterial PDT and ordinary PDT in head and neck cancer. *Proc SPIE*. 1996; 2675: 76–9.
 32. Bloznelytė L, Čepulis V. Intraarterinis fotodinaminis burnos gleivinės ir ryklės navikų gydymas. *Medicina*. 1995; 31(4): 227–30.
 33. Baker SR, Wheeler R. Intraarterial chemotherapy for head and neck cancer. Part 1: theoretical considerations and drug delivery systems. *Head Neck Surg*. 1983; 6(2): 664–82.
 34. Broek GB, Rasch CRN, Pameijer FA, Peter E, Brekel MWM, Tan IB et al. Pretreatment probability model for predicting outcome after intraarterial chemoradiation for advanced head and neck carcinoma. *Cancer*. 2004; 101(8): 1809–17.
 35. Tohnai I. Chemotherapy using intra-arterial infusion for oral cancer. *Nagoya J Med Sci*. 2006; 68: 101–8.
 36. Ishii A, Korogi Y, Nishimura R, Kawanaka K, Ikushima I, Hirai T et al. Intraarterial infusion chemotherapy for head and neck cancers: evaluation of tumor perfusion with intraarterial CT during carotid arteriography. *Radiat Med*. 2004; 22(4): 254–9.
 37. Ikushima I, Korogi Y, Ichii A, Hirai T, Yamura M, Nishimura R et al. Superselective arterial infusion chemotherapy for squamous cell carcinomas of the oral cavity: histopathologic effects on metastatic neck lymph nodes. *Eur Arch Otorhinolaryngol*. 2007; 264: 269–75.
 38. Nakasato T, Katoh K, Sone M, Ehara S, Tamakawa Y, Hoshi H et al. Superselective continuous arterial infusion chemotherapy through the superficial temporal artery for oral cavity tumors. *AJNR Am J Neuroradiol*. 2000; 21(10): 1917–22.

Laima Bloznelytė-Plėšnienė, Aleksandras Mordas,
Vytautas Čepulis, Jonas Venius, Jurgita Liutkevičiūtė-
Navickienė, Laimutė Rutkovskienė, Valerijus Ostapenko,
Konstantinas Povilas Valuckas

BURNARYKLĖS NAVIKŲ INTRAARTERINĖ FLUORESCENCINĖ DIAGNOSTIKA

Santrauka

Tikslas. Ankstyva burnaryklės navikų, tiek pirminių, tiek recidyvų, diagnostika pagerina gydymo rezultatus. Fluorescencinė diagnostika (FD) padeda nustatyti tiksliai burnaryklės navikų ribas bei ankstyvus recidyvus. Ypač tai aktualu, kai recidyvai yra randinami audinyje. Deja, burnaryklėje kartais matomas „artefaktinis“ sveiko audinio švytėjimas, kurį dažniausiai sukelia burnaryklės mikroflora. Nauja FD metodika – intraarterinė FD – turėtų padėti išvengti šio švytėjimo ir padidinti FD efektyvumą, jautrumą ir specifiškumą.

Tiriamieji ir metodai. Diagnozuojant piktybinius burnaryklės navikus, 84 pacientams buvo taikyta fluorescencinė diagnostika, 7 pacientams – intraarterinė fluorescencinė diagnostika (i/aFD). Kaniuliuavus paviršinę smilkininę arteriją, per ją į naviką suleista 10 mg fotofrino. Prieš fotofrino suleidimą ir tuoj po jo, po 1 val. ir 4 val. tiek sveiki, tiek navikiniai burnaryklės audiniai buvo tiriami apšvietus juos violetine 405 nm šviesa. Kartu atlikta keturių skirtingų burnaryklės taškų bei vėžinio audinio spektroskopinė analizė, kurios metu vertinta tiek audinių autofluorescencija, tiek fotofrino indukuota fluorescencija. Iš visų fluorescuojančių ir iš aplinkinių nefluorescuojančių vietų paimta medžiaga morfologiniams tyrimams. Buvo tiriamos trys skirtingos grupės: 1) 30 sveikų savanorių, kuriems burnaryklės audiniai buvo tiriami nesuleidus fotosensibi-

lizatoriaus ir apšviečiant juos violetine 405 nm šviesa; 2) 20 pacientų, kuriems burnaryklės piktybiniai navikai diagnozuoti sisteminė (intraveninė) FD; 3) 60 pacientų, kuriems piktybinių, bet ne burnaryklės, navikų gydymui taikyta sisteminė fotodinaminė terapija ir kartu FD ir kuriems burnaryklės audiniai buvo tiriami apšviečiant juos violetine 405 nm šviesa. Visų grupių žmonėms buvo atlikta keturių skirtingų burnaryklės taškų spektroskopinė analizė ir įvertinta audinių autofluorescencija, o 2 ir 3 grupių pacientams – ir fotofrinu indukuota fluorescencija. Iš visų fluorescuojančių ir iš aplinkinių nefluorescuojančių vietų paimta medžiaga morfologiniams tyrimams.

Rezultatai. Taikant tiek sisteminę, tiek i/a FD, violetine šviesa apšviestas navikas švytėjo avietine spalva, o švytėjimo ribos sutapo su naviko ribomis. Sveiki burnaryklės audiniai nešvytėjo. Dvidešimčiai

antros ir trečios grupių pacientų, kuriems taikyta sisteminė FD, buvo matyti „artefaktinis“ švytėjimas. Nei vienam pacientui, kuriam taikyta i/a FD, artefaktinis švytėjimas nepasireiškė. Preliminariais spektroskopinių tyrimų duomenimis, intraarterinė fotofrino injekcija sukėlė nedidelę apie naviką esančių sveikų audinių fluorescenciją, tuo tarpu navikiniai audiniai fluorescavo labai intensyviai.

Išvados. Fluorescencinė diagnostika padeda anksti nustatyti tiek pirminį, tiek recidyvuojantį burnaryklės vėžį. Šio diagnostinio metodo taikymą kartais apsunkina „artefaktinis“ sveiko audinio švytėjimas. Intraarterinė FD padeda išvengti „artefaktinio“ švytėjimo, mažiau sunaudojama brangaus sensibilizatoriaus. Be to, pacientui nebereikia mėnesį vengti saulės ir ultravioletinių spindulių.

Raktažodžiai: fluorescencinė diagnostika, burnaryklės vėžys, intraarterinė